

Special Topic

Technical Refinements of the Vertical Mammoplasty: A Modified Lejour Approach

Steven G. Wallach, MD

Dr. Wallach is Assistant Clinical Professor of Plastic Surgery, Albert Einstein College of Medicine; Assistant Adjunct Physician, Lenox Hill Hospital; and Assistant Attending Surgeon, Manhattan Eye, Ear, & Throat Hospital, New York, NY.

Although recent refinements in vertical mammoplasty techniques have increased the popularity of the procedure, criticism has continued on the basis of perceived shortcomings in the results. In this paper, a step-by-step description of the author's preferred vertical mammoplasty technique, the modified Lejour approach, is presented. Detailed guidelines are given for preoperative markings to site the proposed new nipple position, ensure breast symmetry, delineate breast displacement and the final medial and lateral extent of skin incision, and minimize "dimple-like" skin indentations at the lower border of the skin excision during closure. Maneuvers for avoiding common pitfalls of the technique are also described, including minimizing the risk of nipple-areolar complex constriction or distortion and avoiding excessive lateral breast fullness. The described vertical mammoplasty technique is safe, reliable, and easily performed in smaller breast reductions and almost all mastopexies. These modifications to the Lejour approach resolve many of the criticisms of vertical mammoplasty procedures. (Aesthetic Surg J 2006;26:179-187.)

The vertical reduction mammoplasty was first described by Dartigues in 1925,¹ followed by a description by Arie in 1957.² Recently, several authors have published vertical mammoplasty technique refinements that have led to more predictable and reproducible results and, consequently, have increased the popularity of the procedure.³⁻¹¹

Nevertheless, criticism of the various vertical mammoplasty procedures has continued. In general, detractors complain about the steep learning curve, the tendency to leave the breasts too large, the inability to treat lateral breast fullness, the unfavorable redraping of the skin envelope leading to irregularities and puckering, especially at the base of the breast, the greater potential for a superiorly displaced nipple-areola complex (NAC), and finally, the development of the tear-drop NAC deformity.

My preferred vertical mammoplasty technique is a modified Lejour approach. I perform this technique for patients who meet the following criteria:

- Removal of 750 gm of tissue or less from each breast (1500 gm total for both breasts)
- Moderate to good skin elasticity
- A superior pedicle that will be 10 cm or less in length

For those patients who meet the first 2 criteria but would otherwise require a superior pedicle length between 10 and 12 cm, I will sometimes opt to perform a superomedial pedicle using a vertical closure.⁸ For surgeons with more experience using this technique, larger reductions (around 1000 gm/breast) can probably be performed successfully. However, for larger breast reductions (>1000 gm), patients with poor skin quality, or those who would require longer superior pedicle lengths, I will usually perform an inferior pedicle reduction using a Wise pattern.¹²

A step-by-step description of the markings and execution of the technique is presented so that a safe, reliable, and consistent result can be obtained. In addition, maneuvers for avoidance of the common pitfalls of this procedure are described.

Preoperative Markings

The preoperative markings are essential to site the NAC correctly and to adjust skin excision patterns to achieve symmetry. The patient is usually marked while in the standing position in the holding area before entering the operating room. A vertical line is drawn from the midclavicular point through the meridian of each breast; this same mark is also transposed to the breast meridian

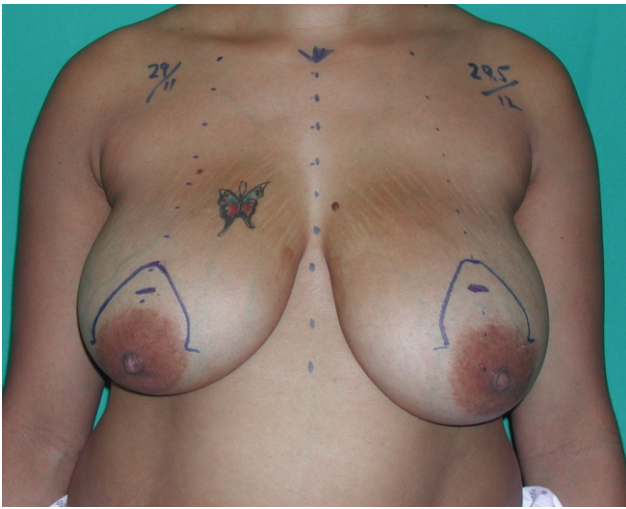


Figure 1. The top of the new areola is marked 2 cm above the new areola position, and a mosque pattern of 14 or 16 cm is drawn.

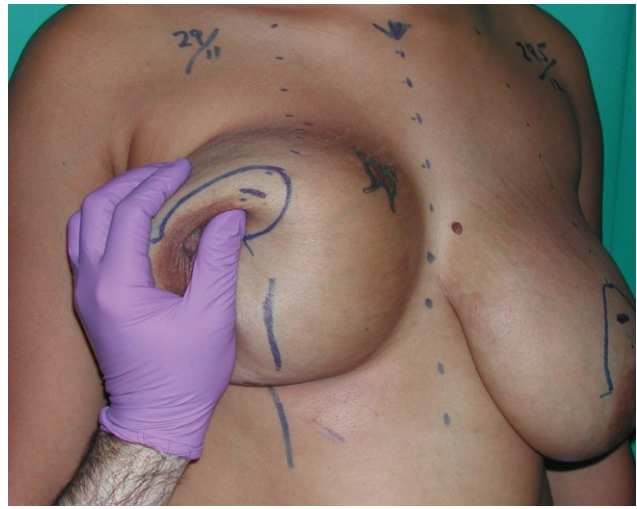

Figure 3. The breast is displaced in an upward and lateral position to determine the medial extent of the skin excision.

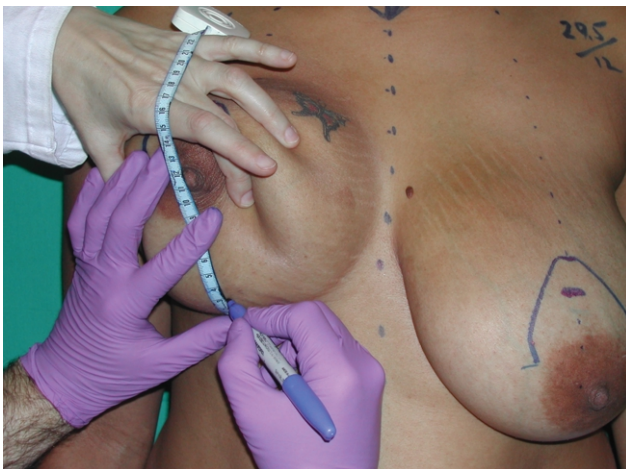

Figure 2. The inferior border of the skin excision is marked at the lower pole of the breast meridian. This is commonly placed between 2 and 4 cm above the inframammary fold.

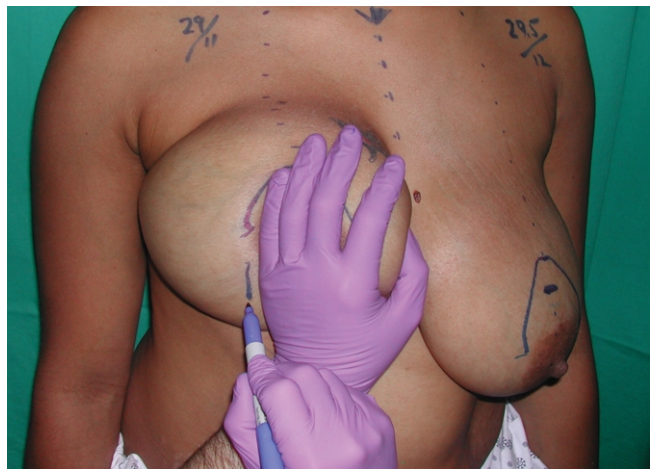

Figure 4. The breast is then displaced upward and medially for the lateral extent of the skin excision. About halfway between the base of the mosque and the inferior breast skin excision marks, a vertical line is drawn to align with the breast meridian at the inframammary fold.

at the inframammary fold. There is a tendency for the NAC to “ride a little high” in the vertical technique. Consequently, the NAC is marked slightly lower than when performing an inferior pedicle reduction/mastopexy using a Wise pattern. This mark often corresponds to the inframammary fold.

I use 3 guides to site the new nipple position:

1. Palpation of the meridian position on the breast directly over the inframammary fold
2. Comparison of this point to the position of the inframammary fold when viewed from a lateral patient position

3. Measurement of the distance from the sternal notch to the proposed new nipple site

The final nipple position is set after reviewing these guides.

Once the new nipple position is chosen, the opposite breast is assessed for symmetry. The top of the new areola position is marked 2 cm above the proposed new nipple position. A mosque pattern is drawn, starting at the proposed new superior border of the areola (Figure 1). This is the only time a prefabricated template is used, as I find it difficult to draw the mosque freehand and create a symmetrical pattern for both breasts. Templates

of 14 or 16 cm are used for smaller or larger final areola diameters, respectively, with the 16-cm template being preferred. If the areola is wider than the pattern chosen, the markings are adjusted as much as possible to avoid leaving pigmented areola skin outside the deepithelialized pattern.

The inferior border of the skin excision is marked at the lower pole of the breast meridian. This is commonly placed between 2 and 4 cm above the inframammary fold. Smaller breasts are marked at 2 cm above the fold, and larger breasts are marked closer to 4 cm (Figure 2).

It is important to delineate the proper amount to displace the breast to determine the final medial and lateral extent of skin excision within the pattern. The breast is displaced in an upward and lateral position to determine the medial extent of the skin excision, and upward and medial for the lateral extent of the skin excision. About halfway between the base of the mosque and the inferior breast skin excision marks, a vertical line is drawn to align with the breast meridian at the inframammary fold. This is performed for the medial and lateral extent of the skin excision (Figures 3 and 4). These lines are then connected in a gentle curve to the mosque pattern, superiorly and inferiorly to the original mark made 2 to 4 cm above the inframammary fold. There is often more skin excised along the lateral margin that is later “cheated in” during the final skin closure.

A “divot” or “dimple-like” indentation of the skin may develop at the lower border of the skin excision during the final closure. Several maneuvers are used to try to minimize this occurrence. First, when marking the patient, the inferior border of the skin excision at the base of the breast is marked so that it forms a V shape. Several authors have suggested making this base excision very round, more like a U shape or a semicircle.^{5,8} I feel that if the inferior breast skin excision is too wide, when the edges are approximated, they will tend to pucker inward and create a “divot.” Other maneuvers used to minimize this depression are described in the section on the final closure.

A technical error can occur if the breast is displaced too much during the initial marking, resulting in a wider pattern than necessary to easily close the breast skin. The skin envelope will then become too tight during final closure, resulting in the development of a depression from the tight skin closure in some patients when they raise their arm above the head. Markings for symmetry between the 2 breasts are assessed, keeping in mind that it is the parenchymal sutures that provide the new breast shape, not the skin closure.

Operative Procedure

The patient is placed in a supine position and given general anesthesia. Sequential compression devices are placed on the lower extremities, and the patient receives perioperative antibiotics prior to the first incision.

The new NAC circumference is marked, commonly with a 38- or 42-mm cookie cutter. The area surrounding the superior pedicle is deepithelialized, leaving a rim of deepithelialized skin 1 to 2 cm along the inferior pole of the NAC.

The skin within the excision pattern, below the pedicle, is then excised. This maneuver allows for better visualization of the parenchyma so that the vertical pedicle and both the medial and the lateral pillars can be easily created. This differs from Lejour’s description in that she maintains the skin attachment to the parenchyma and resects the skin in conjunction with the excess central and inferior breast tissue as a single unit.⁵ If the surgeon is not careful, too much breast tissue from this region can be removed when performing this maneuver, so that the NAC can then become strangulated when the pillars are approximated in the midline. Furthermore, it may not be possible to easily position the NAC in the mosque pattern during final inset.

As described by Lejour,⁵ the skin of the inferolateral, inferior, and inferomedial aspects of the breast is undermined. The inframammary fold is marked, as well as the position just superior to the base of the mosque pattern toward the lateralmost and medialmost aspects of the inframammary fold, creating a triangular region of undermining (Figure 5). The undermining of this area allows for better visualization for creation of the pillars and vertical pedicle, and also minimizes the potential for puckering of the skin during the final closure. These flaps are elevated evenly at the level of the breast capsule (about 5 mm thick) (Figure 6). If the flaps are made thicker, I agree with Lejour that the skin will not drape properly over the breast upon closure. If the flaps are not even, irregularities will develop when the skin is redraped over the contoured parenchyma during the final closure. Undermining is extended 1 to 2 cm superiorly along the border of the mosque pattern to allow for easier redraping of the skin at the base of the NAC closure. In addition, a back-cut is made along the lateral and medial borders of the vertical pedicle to allow for greater mobility of the vertical pedicle upon inseting (Figure 7). A long vertical pedicle will often require a larger back-cut on either side of the mosque pattern, toward the 9 o’clock and 3 o’clock positions, respectively. Furthermore, skin flaps are elevated with scissors to avoid unnecessary heat from a cautery.

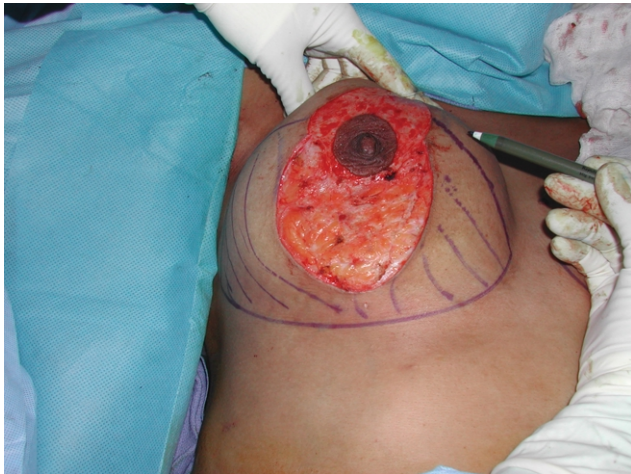

Figure 5. The inframammary fold is marked, as well as the position just superior to the base of the mosque pattern toward the lateralmost and medialmost aspects of the inframammary fold.

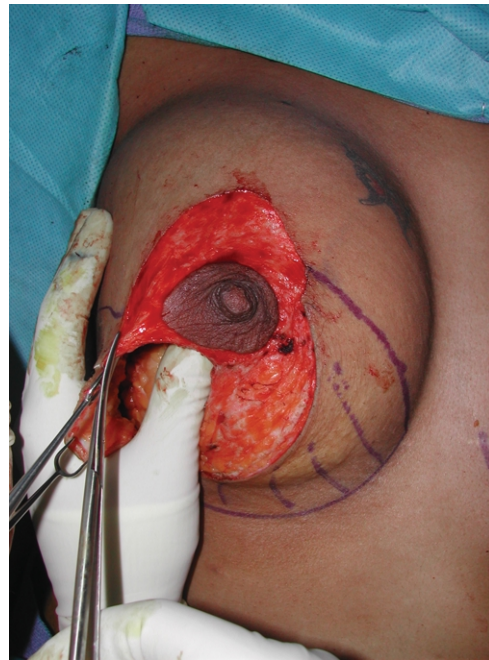


Figure 7. The skin flap is undermined 1 to 2 cm superiorly along the border of the mosque pattern to allow for easier redraping of the skin at the base of the NAC closure.

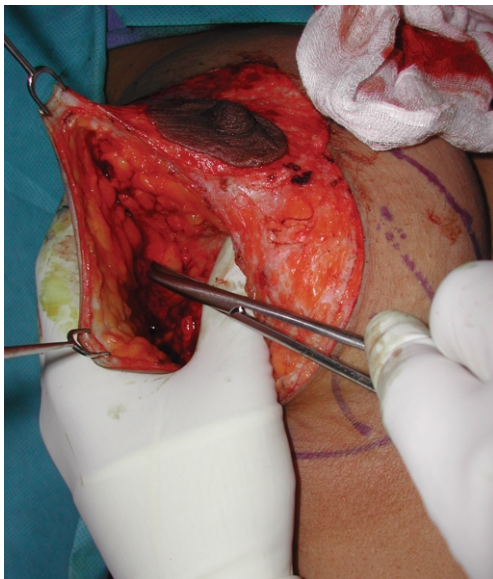

Figure 6. These flaps are elevated evenly at the level of the breast capsule (about 5 mm thick).

The central tunnel is created at the level just above the pectoralis fascia and dissected cephalically to the upper margin of the breast (Figure 8). One hand is placed in the tunnel, and then the medial and lateral pillars as well as the vertical pedicle are delineated. Again, this is the reason why the skin within the pattern is removed, as described previously. A vertical midline is drawn to divide the medial and lateral pillars evenly. The pillars and vertical pedicle are then created in a very controlled fashion (Figure 9). The tissue from each pillar

is transposed across the midline, and the excess is determined (Figure 10). If a mastopexy is performed without removing any breast tissue, then the proposed medial and lateral pillars can be imbricated without dividing the two. If this is done, it is often necessary to release the superior pedicle so that the NAC does not become distorted during placement of the imbricating parenchymal sutures. The parenchyma, approximately half the thickness of the tissue, is incised at the junction between the pillars and the base of the superior pedicle to eliminate this potential problem.

For reduction procedures, the tissue to be excised is determined. This is performed in a similar fashion to the technique described by Palumbo et al.⁷ Medial fullness is maintained to the extent possible, and more tissue is removed laterally as necessary. The tissue from each pillar is transposed across the meridian of the breast without significant tension. The tissue marked for excision in a breast reduction is the portion that crosses over the meridian marking along the inframammary fold. This very controlled maneuver allows precise evaluation of the necessary tissue to be removed. It is easy to determine whether or not the NAC and superior pedicle will be constricted.

If the central inferior tissue with the skin is removed as a single unit, and the pillars are too divergent, there is a greater potential for the pillars to be approximated too

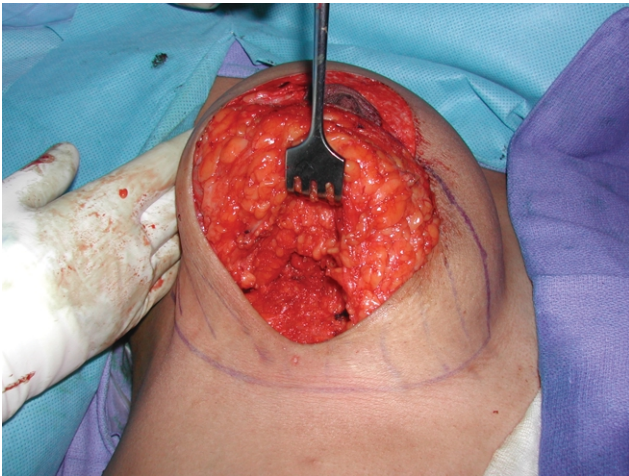


Figure 8. The central tunnel is created at the level just above the pectoralis fascia and dissected cephalically to the upper margin of the breast.

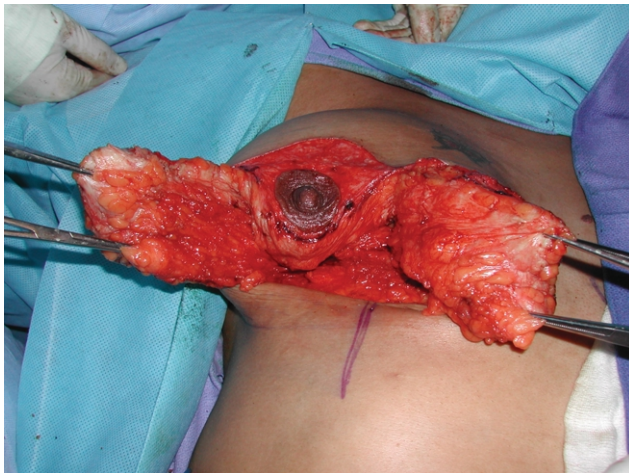


Figure 9. The pillars and vertical pedicle are incised.

tightly. Furthermore, this maneuver can potentially increase the risk of tissue necrosis, as well as potentially constrict or distort the NAC and superior pedicle when final inset and closure are performed.

One argument against using a vertical reduction technique is that patients are sometimes left with too much lateral fullness. The lateral fullness may be the result of not rotating the lateral pillar toward the midline sufficiently when plicating the pillars, or not removing enough tissue laterally. Some surgeons, including Lejour,⁵ have advocated lipoplasty of the breast to remove fullness prior to plicating the pillars.⁵ Others have recommended lipoplasty for final contouring after the plication of the pillars.^{5,7}

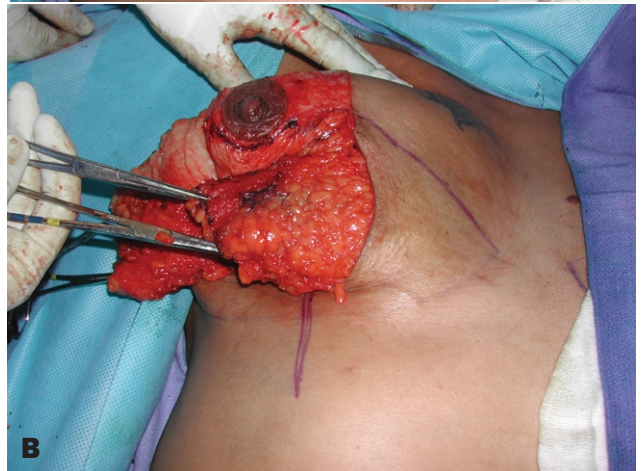
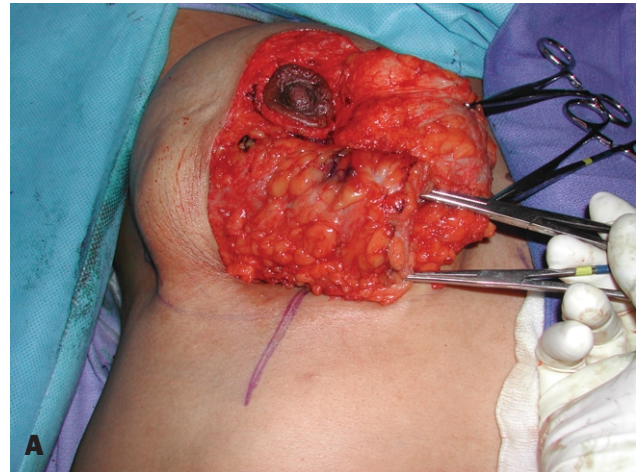


Figure 10. The pillars can be transposed across the meridian line to delineate the amount of tissue from each pillar to be excised. **A,** The transposed lateral pillar. **B,** The transposed medial pillar.

Nevertheless, lipoplasty is not performed during this procedure because, in my opinion, it might increase the risk of fat necrosis and flap loss, as others have also suggested.¹³ In addition, I believe, as do others, that the substance of the pillars would be weakened.⁷ If I feel the patient will have too much lateral fullness after excising tissue from the lateral pillar, then I make a step-cut through the lateral pillar and core out some of the tissue that is part of the deeper tissue of the lateral pillar (Figure 11). By removing this tissue and not the portion adherent to the skin, irregularities in the skin are avoided. This deeper tissue also cores out fairly easily. Removal of tissue from the superior pedicle is the final option but is avoided because, in my experience, it is the tissue of the superior pedicle that provides the superior fullness that patients desire.

Commonly, a small “pennant” or flag of tissue at the lower inferomedial portion of the pillar is also removed

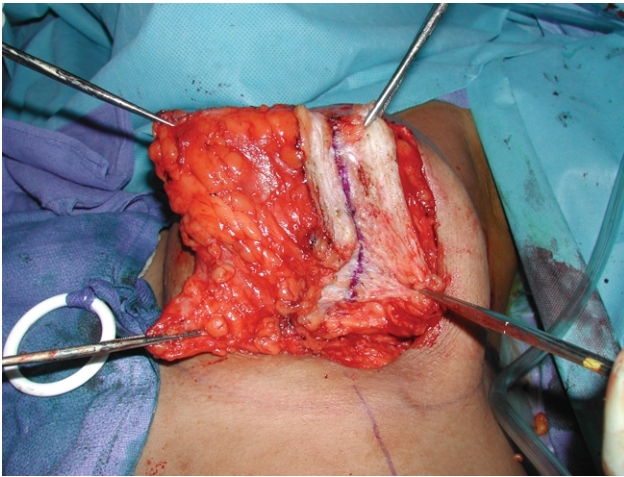


Figure 11. A step-cut through the lateral pillar can be made to core out some of the deeper breast tissue that is part of the lateral pillar. This can help reduce lateral fullness.

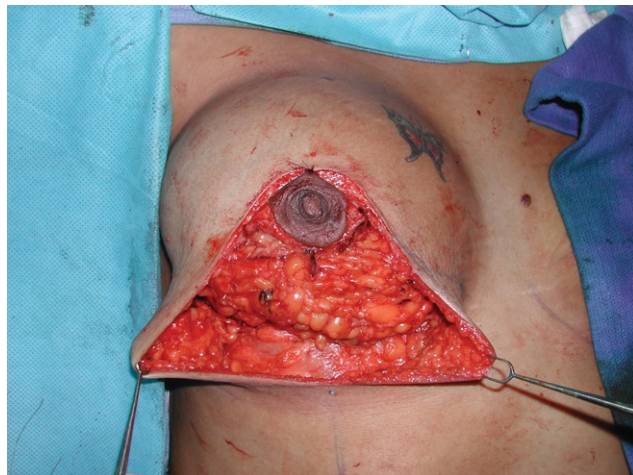


Figure 12. Final shape of the breast after approximating the 2 pillars. Note that the superior pedicle is positioned comfortably without tension. The lower pole of the breast should have a rounded shape, almost like an implant. If pennants are still present at the base, they should be removed to create this shape at the lower border.

during the resection. Removing this tissue prior to approximating the pillars eliminates the need to “round off” the lower breast pole after the pillars are sutured together. For mastopexy patients, this tissue can be folded superiorly and under the pillars to provide more fullness.

The NAC is then inset at the 12 o’clock position before the pillars are sewn together. Lejour⁵ describes placement of a suture from the underside of the superior pedicle to a position high on the chest to elevate the tissue. This maneuver is not performed, as I do not believe that it provides any benefit. Furthermore, others have

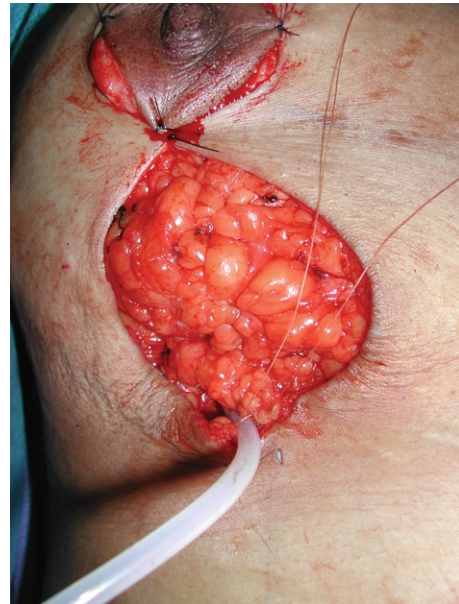


Figure 13. An absorbable suture from the inferiormost portion of the skin to the base of the parenchymal pillars is placed. A divot at the inframammary fold is avoided (1) by making the lower incision V-shaped as opposed to U-shaped, and (2) by avoiding placing the skin suture to the chest wall. The skin is gathered and sewn from the lower pole up toward the NAC, taking small “bites” of breast parenchyma with each suture placement.

cautioned that this suture caused some complications with NAC puckering that required revision.⁷

A narrow Deaver or Richardson retractor is placed under the superior pedicle and facilitates alignment of the pillars. Usually, 3 to 4 absorbable sutures are placed from the top down to align the pillars, minimize constriction around the NAC, and cone the breast. The lowest sutures tend to cone the breast the most. I approximate the pillars without tension to minimize the risk of tissue strangulation and potential necrosis. For mastopexy patients, the tissue is imbricated during pillar approximation to provide more fullness.

After the pillars are approximated, the lower pole is evaluated for adequate shape. If the pennants are not removed earlier in the procedure, then they are removed at this stage. It is important to have a rounded lower pole appearance, similar to the shape obtained with a breast implant (Figure 12).

The NAC is tacked into place, and a closed suction drain is placed in the lower lateral aspect of the wound. It is very common to have a length discrepancy between the lateral and medial skin closure margins. The lateral skin must be “cheated in” to compensate for the discrepancy. A common mistake is creating a “divot” or “dim-

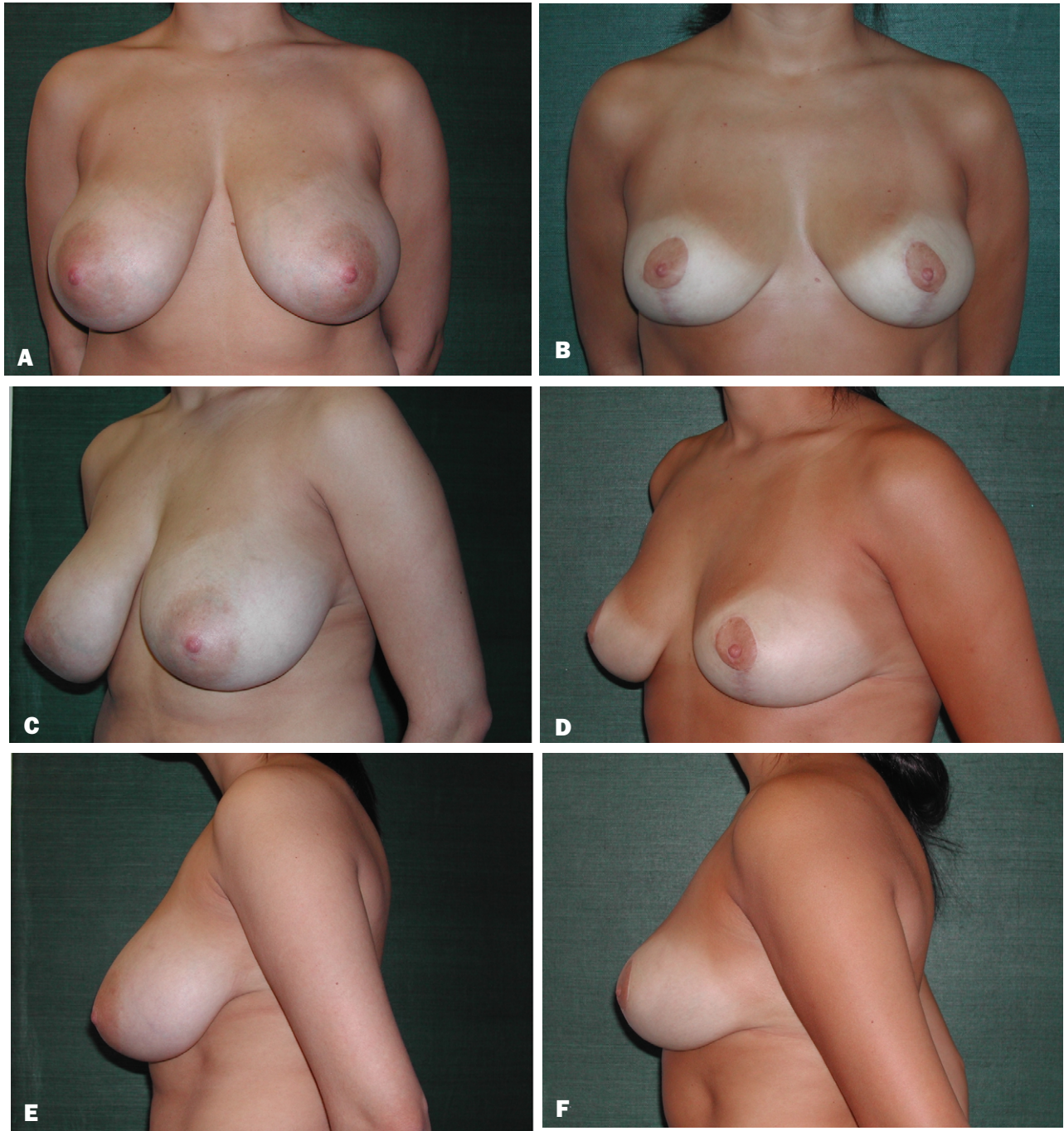


Figure 14. A, C, E, Preoperative views of a 25-year-old woman who underwent a vertical breast reduction using a superior pedicle. B, D, F, Postoperative views 6 months after removal of 460 gm from the right breast and 410 gm from the left breast.

ple-like” depression at the inferiormost aspect of the wound closure. As stated earlier, one cause of this deformity is the wide skin excision at the base of the breast from designing it as a U shape or semicircle, causing the skin to pull together tightly at the base of the breast during final closure. Additionally, this can also occur if the

suture from the inferiormost portion of the skin closure is placed to the pectoralis muscle fascia. An absorbable suture is placed from the inferiormost portion of the skin to the base of the approximated parenchyma. The skin is gathered, and the closure is performed from the bottom, working superiorly and attaching the deep dermis of

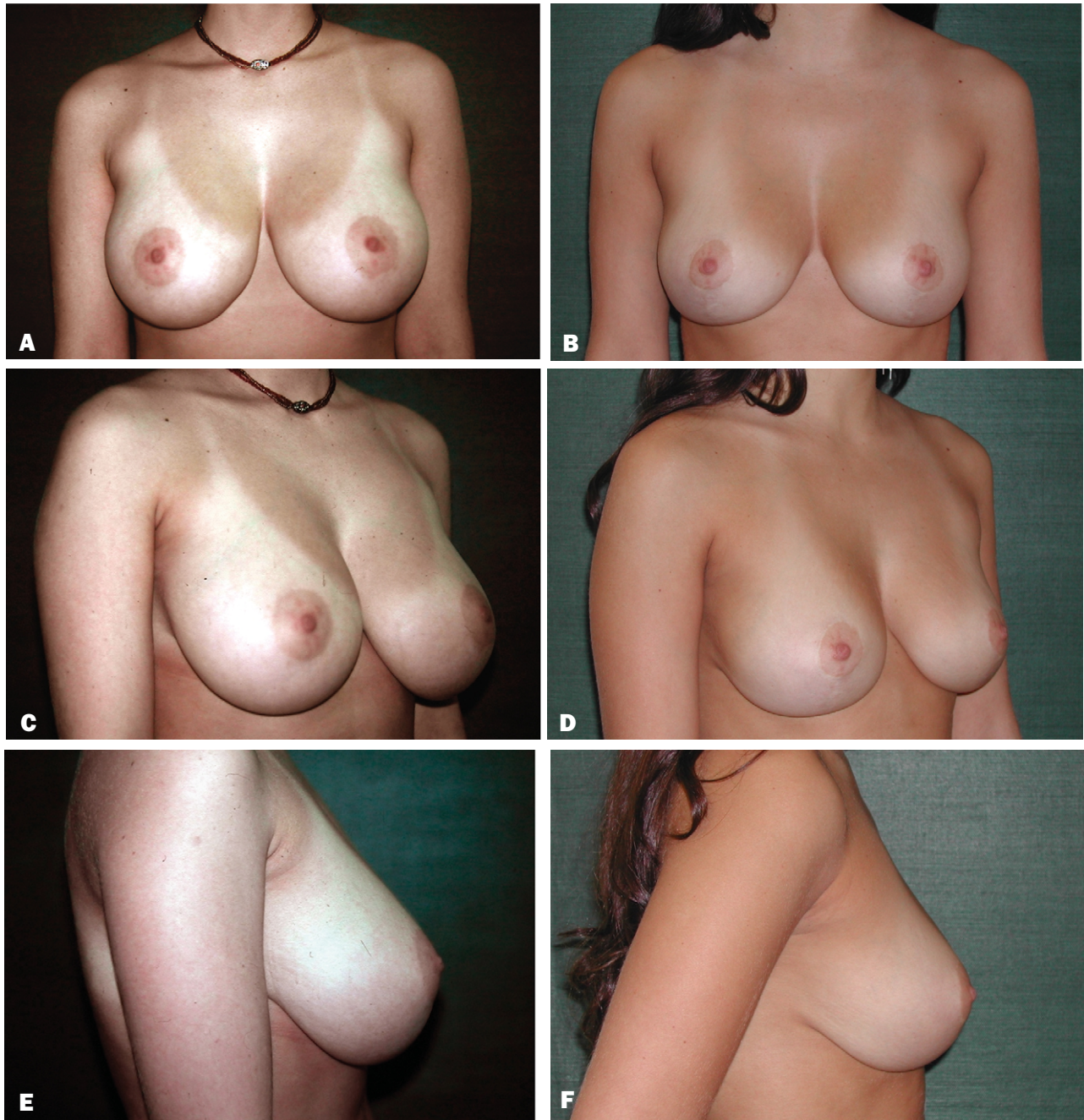

Figure 15. A, C, E, Preoperative views of a 24-year-old woman who underwent a vertical breast reduction using a superior pedicle. B, D, F, Postoperative views 2.5 years after removal of 340 gm from the right breast and 340 gm from the left breast.

both sides of the skin to the breast parenchyma along the meridian (Figure 13). Working from the “bottom up” provides better redraping of the skin, especially along the lower pole, and brings the final scar above the inframammary fold.

After the NAC is sutured in place with absorbable sutures, a running absorbable intracuticular suture is

placed to close the vertical incision. To minimize a “teardrop” NAC from occurring, the suture is started just below the 6 o’clock position of the NAC. It is secured for the first 2 cm. The suture is then knotted, and the remainder of the suture is placed. The remaining length is then “cinched” or “purse-stringed” so that the final length of the closure from NAC to the fold is approximately 7 to 9

cm in length. This length is probably not critical in the long run, but it may help to redrape the skin around the parenchyma during the early postoperative period.¹⁴ Results are shown in [Figures 14](#) and [15](#).

Conclusion

A technique for breast reduction/mastopexy must be safe, reliable, reproducible, and easily performed. I have used the described technique during the past 8 years, and it has been taught successfully to many plastic surgery residents. Applying the modifications described should eliminate most, if not all, of the drawbacks that have inhibited the general acceptance of the vertical technique for most smaller breast reductions and almost all mastopexies. ■

References

1. Dartigues L. Traitement chirurgical du prolapsus mammaire. *Arch Franco Belg Chir* 1925;28:313.
2. Arie G. A new technique of mammoplasty. *Rev Latinoam Cir Plast* 1957;3:23.
3. Lassus C. A technique for breast reduction. *In Surg* 1970;53:69-72.
4. Marchac D, De Olarte G. Reduction mammoplasty and correction of ptosis with a short inframammary scar. *Plast Reconstr Surg* 1982;69:45-55.
5. Lejour M. Vertical mammoplasty and liposuction of the breast. *Plast Reconstr Surg* 1994;94:100-114.
6. Hammond DC. Short scar periareolar inferior pedicle reduction (SPAIR) mammoplasty. *Plast Reconstr Surg* 1999;103:890-901.
7. Palumbo SK, Shifren J, Rhee C. Modifications of the Lejour vertical mammoplasty: analysis of results in 100 consecutive patients. *Ann Plast Surg* 1998;40:354-359.
8. Hall-Findley EJ. A simplified vertical reduction mammoplasty: shortening the learning curve. *Plast Reconstr Surg* 1999;104:748-759.
9. Ramirez O. Reduction mammoplasty with the 'owl' incision and no undermining. *Plast Reconstr Surg* 2002;109:512-522.
10. Motturra A. Circumvertical reduction mammoplasty. *Aesth Surg J* 2000;20:199-204.
11. Chen C, White C, Warren S, Cole J, Isik F. Simplifying the vertical reduction mammoplasty. *Plast Reconstr Surg* 2004;113:162-172.
12. Robbins TH. A reduction mammoplasty with the areola-nipple based on an inferior dermal pedicle. *Plast Reconstr Surg* 1977;59:64-67.
13. Beer GM, Spicher I, Cierpka KA, Meyer VE. Benefits and pitfalls of vertical scar breast reduction. *Br J Plast Surg* 2004;57:12-19.
14. Wallach SG. Avoiding the teardrop-shaped nipple areola complex (NAC) in the vertical mammoplasty. *Plast Reconstr Surg* 2000;106:1217-1218.

Accepted for publication November 30, 2005.

Reprint requests: Steven Wallach, MD, 1049 5th Avenue, #2D, New York, NY 10028.

Copyright © 2006 by The American Society for Aesthetic Plastic Surgery, Inc.

1090-820X/\$32.00

doi:10.1016/j.asj.2006.01.005