

VOLUME 106 • NUMBER 5 • OCTOBER 2000



AMERICAN SOCIETY OF  
PLASTIC SURGEONS

Full Text  
Online Available  
October 2000

# Plastic and Reconstructive Surgery®

Journal of the American Society of Plastic Surgeons

Official Organ of the American Association of Plastic Surgeons

Official Organ of the American Society for Aesthetic Plastic Surgery, Inc.

Official Organ of the American Society of Maxillofacial Surgeons



<http://www.plasreconsurg.com>



histopathologic examinations, the presence of a solid mass in a breast that suffered previously from cancer cannot always be addressed by logical explanations, reassurance, and encouragement to the patient. In addition, fat necrosis can deform the breast and may create great physical and psychological discomfort for the patient. Occasionally, surgical correction is required. Moreover, the operation may result in major defects of the reconstructed breast.

Hence, to avoid invasive procedures, we advise our patients to perform an intensive deep-pitting massage with their (or their partner's) index finger. The massage should be performed during the first weeks after the TRAM operation, as soon as fat necrosis is suspected.

To relieve the pain induced by the massage and to protect the overlying skin, we suggest that our patients apply petroleum jelly to the skin before the massage. We advise massaging the area for about 10 minutes 3 times a day. The procedure should be continued until softening of the tissues is achieved. We have noticed that the earlier the massage is started, the better the outcome.

Based on our encouraging experience, we hypothesize that massage procedure breaks down mechanically the developing fat necrosis into small fragments, thus enhancing clearance of the necrotic tissue by the lymphatic system and avoiding calcifications. In addition, a more soft, regular, and smooth breast shape is achieved.

Abraham Amir, M.D.  
 Ram Silfen, M.D.  
 Daniel J. Hauben, M.D.  
 Department of Plastic and Reconstructive  
 Surgery and Burn Unit  
 Rabin Medical Center  
 Beilinson Campus  
 Petah-Tikva, Israel 49100  
 ra\_amir@netvision.net.il

#### REFERENCES

1. Kroll, S. S., Gherardini, G., Martin, J. E., et al. Fat necrosis in free and pedicled TRAM flaps. *Plast. Reconstr. Surg.* 102: 1502, 1998.
2. Yanaga, H., Tai, Y., Kiyokawa, K., et al. An ipsilateral superdrained transverse rectus abdominis myocutaneous flap for breast reconstruction. *Plast. Reconstr. Surg.* 103: 465, 1999.
3. Restifo, R. J., Ahmed, S. S., Rosser, J., et al. TRAM flap perforator ligation and the delay phenomenon: Development of an endoscopic/laparoscopic delay procedure. *Plast. Reconstr. Surg.* 101: 1503, 1998.
4. Yamamoto, Y., Nohira, K., Sugihara, T., et al. Superiority of the microvascularly augmented flap: Analysis of 50 transverse rectus abdominis myocutaneous flaps for breast reconstruction. *Plast. Reconstr. Surg.* 97: 79, 1996.
5. Marck, K. W., Van der Biezen, J. J., and Dol, J. A. Internal mammary artery and vein supercharge in TRAM flap breast reconstruction. *Microsurgery* 17: 371, 1996.

#### AVOIDING THE TEARDROP-SHAPED NIPPLE-AREOLA COMPLEX IN VERTICAL MAMMAPLASTY

Sir:

In the past I have found that during final closure of a vertical mammoplasty, cinching of the intracuticular absorbable suture of the vertical incision often resulted in a teardrop

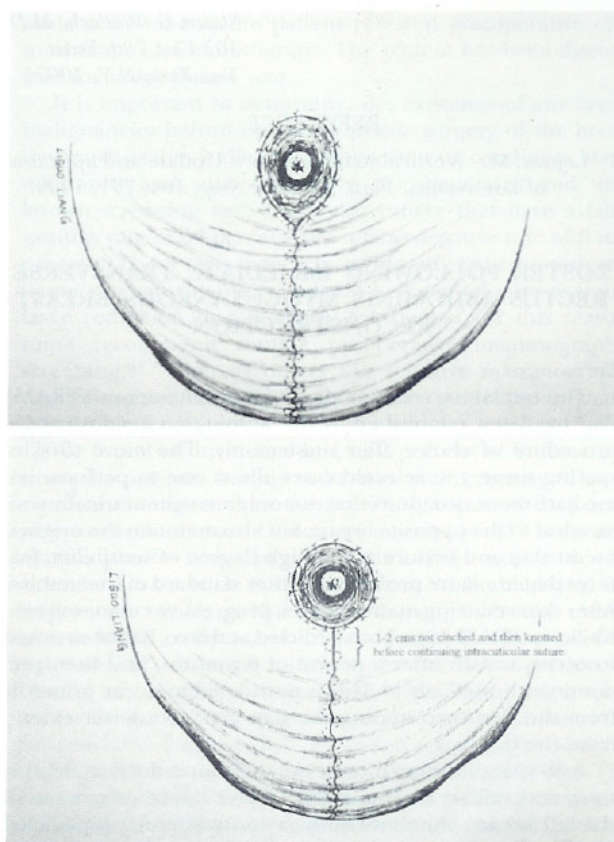


FIG. 1. (Above) Final closure of vertical mammoplasty with teardrop shaped nipple-areola complex. (Below) Final closure of vertical mammoplasty with rounder nipple-areola complex after interrupting the intracuticular suture so that the first 1 to 2 cm are not cinched.

shape to the nipple-areola complex (Fig. 1, above). By the 3- to 6-month follow-up, this usually had improved to some degree. Nevertheless, I have found that the nipple-areola complex would not revert to a completely round shape.

To correct this problem I use a simple method. As Lejour described, the deep dermis of the vertical incision is closed with a 3-0 absorbable suture, approximating the deep dermis to the underlying breast parenchyma.<sup>1</sup> Starting at the inferior border of the nipple-areola complex, or what is the superior portion of the vertical closure, I perform the intracuticular repair with a 4-0 absorbable suture. In the past, I would cinch the entire length of the vertical closure so that the final length was shorter than the preoperative length (usually between 7 and 10 cm). Because the cinching was along the entire length of the closure, the nipple-areola complex would often be pulled inferior and assume a teardrop shape.

I now start the repair as described, except that after the first 1 to 2 cm of intracuticular closure I knot the suture without cinching it, thus preventing pursing along the first 1 to 2 cm (Fig. 1, below). This prevents the superior aspect of the vertical incision from being cinched down and avoids tethering of the inferior border of the nipple-areola complex. The remainder of the vertical incision closure is then continued in an intracuticular fashion and is cinched to obtain the desired final length. After performing this simple maneuver, I have found that the nipple-areola complex maintains a rounder, more natural appearance that persists over time.



Steven G. Wallach, M.D.  
103 East 78th Street  
New York, N.Y. 10021

## REFERENCE

1. Lejour, M. Vertical mammoplasty: Update and appraisal of late results. *Plast. Reconstr. Surg.* 104: 771, 1999.

### ZOSTER FOLLOWING IMMEDIATE TRANSVERSE RECTUS ABDOMINIS MYOCUTANEOUS BREAST RECONSTRUCTION

Sir:

The transverse rectus abdominis myocutaneous (TRAM) flap has been established as the autologous reconstructive procedure of choice after mastectomy. The move to skin-sparing surgery in selected cases allows one to perform immediate reconstructions that not only are volumetrically symmetrical to the opposite breast, but also maintain the original breast skin and texture and a high degree of sensibility, features that are more problematic after standard mastectomies. After skin-reducing mastectomies, progressive cutaneous sensibility in TRAM flaps, both pedicled and free, has been noted to occur, usually after a period of 6 months, and then predominantly medially.<sup>1-5</sup> This is postulated to occur primarily from the skin surrounding the flap and, to a lesser extent, from the bed.<sup>6</sup>

A 39-year-old woman underwent a skin-reduction mastectomy and axillary clearance for a T2N1 ductal carcinoma of the left breast. Simultaneously, a contralateral, unipedicled TRAM flap and nipple-areola reconstruction were per-

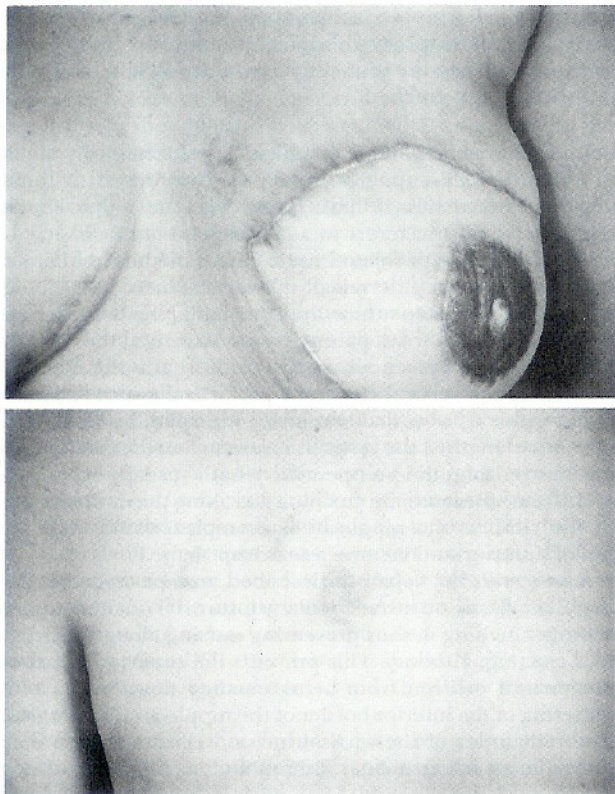


FIG. 1. (Above) Left TRAM flap breast reconstruction. Note the fading rash on the medial mastectomy flap. (Below) Zosteriform rash on the left side of the back.

formed, along with a symmetrization right reduction mammoplasty. The patient's postoperative course was uncomplicated. Chemotherapy was commenced 1 month after the surgery. Two weeks later, the patient developed a mild zosteriform rash in a dermatomal distribution on her left hemithorax. This settled without specific therapy over a 2-week period. The rash was present on her back and to the edge of the medial mastectomy flap but not on the TRAM skin paddle. No vesicles were present on the skin paddle (Fig. 1).

It is likely that the virus remained latent in the dorsal root ganglion and was reactivated by the immunosuppressive chemotherapy. The virus then spread along the intercostal nerve and into the mastectomy skin flap, as reported in a previous case study.<sup>7</sup> The presence of vesicles on the medial mastectomy flap, despite a total mastectomy, indicates that there is continuity of the medial mammary ramus of the anterior cutaneous branch of the intercostal nerve. This may account, in part, for the observation that TRAM flaps tend to develop sensation predominantly medially and, to a lesser extent, centrally and laterally, where the flap is thickest and the lateral cutaneous branch of the intercostal nerve is resected with the mastectomy specimen. This may also have implications for pedicle design and selection in reduction mammoplasty, for which a superomedial pedicle may be favored.<sup>8</sup>

The usual management of such patients involves acyclovir therapy. One should, however, be alert to the possibility of a cutaneous malignancy that mimics herpes zoster. In women, breast cancer accounts for the majority of skin metastases and can mimic shingles very closely. It is recommended that when the lesions are either atypical (papules or nodules rather than vesicopustules) or follow an atypical clinical course, biopsy should be performed to exclude cutaneous metastases.<sup>9,10</sup>

Paul J. Skoll, F.R.C.S.

Donald A. Hudson, F.R.C.S.

Department of Plastic, Reconstructive and  
Maxillo-Facial Surgery  
H53 Old Main Building  
Groote Schuur Hospital  
Cape Town 7925, South Africa  
skollp@uctgsh1.uct.ac.za

## REFERENCES

1. Slezak, S., McGibbon, B., and Dellon, A. L. The sensation transverse rectus abdominis musculocutaneous (TRAM) flap: Return of sensibility after TRAM breast reconstruction. *Ann. Plast. Surg.* 28: 210, 1992.
2. Liew, S., Hunt, J., and Pennington, D. Sensory recovery following free TRAM breast reconstruction. *Br. J. Plast. Surg.* 49: 210, 1996.
3. Place, M. J., Song, T., Hardesty, R. A., and Hendricks, D. L. Sensory reinnervation of autologous tissue TRAM flaps after breast reconstruction. *Ann. Plast. Surg.* 38: 19, 1997.
4. Blondeel, P. N., Demuyneck, M., Monstrey, S. J., Van Landuyt, K., Matton, G., and Vanderstraeten, G. G. Sensory repair in perforator flaps for autologous breast reconstruction: Sensational or senseless? *Br. J. Plast. Surg.* 52: 37, 1999.
5. Lehmann, C., Gumener, R., and Montandon, D. Sensibility and cutaneous reinnervation after breast reconstruction with musculocutaneous flaps. *Ann. Plast. Surg.* 26: 325, 1991.
6. Turkof, E., Jurecka, W., Sikos, G., and Piza-Katzer, H. Sensory recovery in myocutaneous noninnervated free flaps: A morphologic, immunohistochemical, and